

REVIEW ARTICLES

MEDICAL PROGRESS

SEVERE ADVERSE CUTANEOUS REACTIONS TO DRUGS

JEAN CLAUDE ROUJEAU, M.D.,
AND ROBERT S. STERN, M.D.

ALTHOUGH the rate of acute severe adverse cutaneous reactions to medications is low, these reactions can affect anyone who takes medications and can result in death or disability.¹ Even a small number of cases associated with a particular drug may alter the recommendations for its use.²⁻⁴ Prompt differentiation of severe adverse cutaneous reactions from less serious skin disorders may be difficult. Rapid recognition of severe reactions is essential. Prompt withdrawal of the offending drug is often the most important action to minimize morbidity.

Adverse cutaneous reactions to drugs are frequent, affecting 2 to 3 percent of hospitalized patients.⁵ Many commonly used drugs have reaction rates above 1 percent.⁵ Fortunately, most adverse cutaneous reactions are not severe, and few are fatal.

Complications of drug therapy are the most common type of adverse event in hospitalized patients, accounting for 19 percent of such events.⁶ Cutaneous or allergic reactions to drugs are responsible for approximately 3 percent of all disabling injuries during hospitalization.⁶ The reported percentage of cutaneous drug reactions that physicians diagnose as potentially serious varies greatly but is probably about 2 percent.^{7,8} We estimate that about 1 of every 1000 hospitalized patients has a serious cutaneous drug reaction. Each year thousands of outpatients have cutaneous reactions that may result in substantial morbidity or death unless promptly recognized and treated. Not all serious adverse reactions to drugs with a prominent cutaneous component develop rapidly. For example, the distinctive cutaneous changes of eosinophilia-myalgia syndrome cause great morbidity but usually occur after prolonged exposure.⁹

In this article, we shall emphasize the clinical recognition, epidemiology, pathophysiology, and treatment of acute, serious cutaneous adverse reactions.

Table 1 presents the key clinical features of the reactions we shall discuss.

RECOGNITION

Drug eruptions are most often morbilliform or exanthematous (Fig. 1).⁵⁻⁷ They usually fade in a few days but may worsen. In rare instances in which no alternative therapy is available, a drug may be continued in spite of a morbilliform eruption. Unfortunately, a morbilliform eruption is often the initial presentation of more serious reactions including toxic epidermal necrolysis, hypersensitivity syndrome, and serum sickness. Table 2 lists clinical features that should alert the physician that a reaction is serious. When a drug reaction is suspected, the presence of urticaria, blisters, mucosal involvement, facial edema, ulcers, palpable or extensive purpura, fever, or lymphadenopathy almost always necessitates discontinuation of the drug.

Several algorithms have been proposed for the assessment of adverse drug reactions,¹⁰⁻¹² but none have proved to be both sensitive and specific. The following criteria and Tables 1 and 3 provide guidelines for formulating a differential diagnosis. First, alternative causes should be excluded, especially infections, since many infectious illnesses are difficult to distinguish clinically from the adverse effects of drugs used to treat infections. Second, the interval between the introduction of a drug and the onset of a reaction should be examined. Third, any improvement after drug withdrawal should be noted. Fourth, the physician should determine whether similar reactions have been associated with the same compound. Fifth, any reaction on readministration of the drug should be noted.

A skin biopsy is often critical for an accurate diagnosis, but biopsy does not help in establishing whether the disease is drug-induced. In vivo tests include readministration of the drug (rechallenge) and skin tests. Reactions after rechallenge may be worse. Rechallenge should not be performed after a serious reaction.

Skin tests and in vitro tests (such as the radioallergen sorbent test) help diagnose IgE-mediated type I hypersensitivity reactions, especially to penicillin.¹³ In other types of eruptions, skin testing has low sensitivity and specificity.¹⁴ In vitro testing of cellular proliferative responses to drugs is usually not helpful.¹⁵ Although still investigational, in vitro studies of enhanced toxic effects of drugs or drug metabolites on cells may someday aid in the diagnosis and understanding of the pathogenesis of some types of reactions.^{16,17}

STEVENS-JOHNSON SYNDROME AND TOXIC EPIDERMAL NECROLYSIS

Stevens-Johnson syndrome and toxic epidermal necrolysis are two related mucocutaneous disorders with

From the Department of Dermatology, Henri Mondor Hospital, University of Paris XII, Creteil, France (J.C.R.), and Beth Israel Hospital, Harvard Medical School, Boston (R.S.S.). Address reprint requests to Dr. Stern at the Department of Dermatology, Beth Israel Hospital, 330 Brookline Ave., Boston, MA 02215. Supported in part by a grant from INSERM (90-0812).

Table 1. Clinical Features of Selected Severe Cutaneous Reactions Often Induced by Drugs.

DIAGNOSIS	MUCOSAL LESIONS	TYPICAL SKIN LESIONS	FREQUENT SIGNS AND SYMPTOMS	PERCENT DRUG-INDUCED	PERCENT FATAL
Stevens-Johnson syndrome	Erosions usually at ≥ 2 sites	Small blisters on dusky purpuric macules or atypical targets, rare areas of confluence, detachment of $\leq 10\%$ of body-surface area	10-30% of cases involve fever, lesions of the respiratory tract* and gastrointestinal tract	50	<5
Toxic epidermal necrolysis	Erosions usually at ≥ 2 sites	Individual lesions like those seen in Stevens-Johnson syndrome, confluent erythema, outer layer of epidermis separates readily from basal layer with lateral pressure, † large sheets of necrotic epidermis, total detachment of $>30\%$ of body-surface area	Nearly all cases involve fever, "acute skin failure," † leukopenia, lesions of the respiratory tract* and gastrointestinal tract	>80	30
Hypersensitivity syndrome	Infrequent	Severe exanthematous rash (may become purpuric), exfoliative dermatitis	30-50% of cases involve fever, lymphadenopathy, hepatitis,* nephritis,* carditis,* eosinophilia, atypical lymphocytes	>90	10
Small-vessel vasculitis	Infrequent	Palpable purpura, most often on the legs; nodules; ulcerations; urticaria	30-50% of cases involve the gastrointestinal tract,* neuritis, fever, glomerulonephritis*	10	<5
Serum sickness or reactions resembling serum sickness	Absent	Morbiliiform lesions, sometimes with urticaria	Fever, arthralgias	>90	<5
Anticoagulant-induced necrosis	Infrequent	Erythema then purpura and necrosis, especially of fatty areas	Pain in affected areas	100	>10
Angioedema	Often involved	Urticaria or swelling of central part of face	Respiratory distress,* cardiovascular collapse*	>50§	1-6

*Potential cause of death.

†Systemic consequences of widespread injury to the skin, as seen with thermal burns.

‡Nikolsky's sign.

§The figure refers to the percentage among hospitalized patients; a much smaller percentage of all cases are drug-induced.

high rates of morbidity and mortality (Table 1).^{1,18,19} Although the nosology and specific diagnostic criteria for these disorders remain controversial, we believe certain clinical features help define these conditions²⁰ (Tables 1 and 3).

Clinical Features

In 1922, Stevens and Johnson described children with febrile erosive stomatitis, severe ocular involvement, and a disseminated cutaneous eruption of discrete dark-red macules, sometimes with a necrotic center. This became known as Stevens-Johnson syndrome.²¹ In 1956, Lyell introduced the term "toxic epidermal necrolysis" to describe patients with extensive loss of epidermis due to necrosis that leaves the skin surface looking scalded.²² In severe cases, Stevens-Johnson syndrome can include extensive areas of epidermal necrolysis. In most cases of toxic epidermal necrolysis, the discrete red macules typically seen with Stevens-Johnson syndrome occur around larger necrolytic areas. The similarities between the histopathological findings and the drugs responsible suggest that these two conditions are part of a single spectrum.^{18,19,23,24} The term Stevens-Johnson syndrome is also frequently used as a synonym for erythema multiforme major, resulting in confusion. In our opinion, the two are different conditions that are usually clinically distinguishable.²⁰ Patients with erythema multiforme major have typical target lesions, predominantly on the extremities (Fig. 2). Erythema multiforme major usually occurs after infections, especially herpes simplex and mycoplasma, and has a

benign course.²⁵ Patients with widely distributed purpuric macules and blisters (Fig. 3) and prominent involvement of the trunk and face (Fig. 4) are likely to have Stevens-Johnson syndrome, which is usually drug-induced.

Patients may present with a clinical picture of Stevens-Johnson syndrome that evolves to one of toxic epidermal necrolysis within a few days. Fever and influenza-like symptoms unexplained by infectious ill-




Figure 1. A Morbilliform Drug Eruption with Numerous Erythematous Macules and Papules That Vary in Size and Are Symmetrically Distributed.

Most lesions are faint, but some may be slightly infiltrated and resemble urticaria. This exanthematous eruption often starts on the trunk, as in this patient. It may also begin on areas subjected to pressure. The rash may become confluent.

Table 2. Clinical and Laboratory Findings That Should Alert Clinicians That a Drug-Induced Cutaneous Eruption May Be Serious.

Clinical findings	
Cutaneous	
	Confluent erythema
	Facial edema or central facial involvement
	Skin pain
	Palpable purpura
	Skin necrosis
	Blisters or epidermal detachment
	Positive Nikolsky's sign*
	Mucous-membrane erosions
	Urticaria
	Swelling of tongue
General	
	High fever (temperature >40°C)
	Enlarged lymph nodes
	Arthralgias or arthritis
	Shortness of breath, wheezing, hypotensive
Laboratory results	
	Eosinophil count >1000/mm ³
	Lymphocytosis with atypical lymphocytes
	Abnormal results on liver-function tests

*The outer layer of the epidermis separates readily from the basal layer with lateral pressure.

ness often precede the mucocutaneous lesions of these two conditions by one to three days. Burning and pain occur. Initially, these eruptions are symmetrically distributed on the face and upper trunk areas that usually remain the most severely affected.²¹ The rash spreads rapidly and is usually maximal within four days, sometimes within hours. The initial skin

lesions are usually poorly defined macules with darker purpuric centers that coalesce (Fig. 5).

Although precise diagnostic boundaries between the two disorders have not been established, cases with limited areas of epidermal detachment are usually labeled Stevens-Johnson syndrome and those with extensive detachment toxic epidermal necrolysis. We classify cases with detachment of less than 10 percent of the epidermis as Stevens-Johnson syndrome and those with more than 30 percent as toxic epidermal necrolysis.²⁰ In cases with detachment of 10 to 30 percent of the epidermis we consider the two syndromes to overlap.²⁰ In toxic epidermal necrolysis, sheet-like loss of epidermis and raised flaccid blisters, which spread with pressure, often occur, and Nikolsky's sign (i.e., dislodgment of epidermis by lateral pressure) is positive on erythematous areas. With trauma, full-thickness epidermal detachment (Fig. 6) yields exposed, red, sometimes oozing dermis. In other areas, pale necrotic epidermis may remain (Fig. 7).

About 90 percent of patients with each disorder have mucosal lesions, including painful erosions and crusts on any surface (Fig. 8).¹⁸ Impaired alimentation, photophobia, and painful micturition often result. The epithelium of the trachea, bronchi, or gastrointestinal tract may be involved.²⁶⁻²⁸ Often overlooked, these lesions may cause substantial morbidity. About 85 percent of patients have conjunctival lesions.^{18,29,30} These range from hyperemia to extensive pseudo-membrane formation.²⁹⁻³¹ Synechiae between eyelids

Table 3. Factors to Consider in Diagnosing Severe Cutaneous Adverse Reactions and Their Causes.

DIAGNOSIS	DRUGS MOST OFTEN RESPONSIBLE	TYPICAL INTERVAL FROM BEGINNING OF DRUG THERAPY TO ONSET OF REACTION	ALTERNATIVE CAUSES NOT RELATED TO DRUGS	HELPFUL TESTS
Stevens-Johnson syndrome	*	1-3 wk	Postinfectious erythema multiforme major (especially in the case of infection with herpes simplex or mycoplasma)	Skin biopsy with immunofluorescence testing
Toxic epidermal necrolysis	*	1-3 wk		Skin biopsy with immunofluorescence testing
Hypersensitivity syndrome	Anticonvulsants, sulfonamides, allopurinol	2-6 wk	Cutaneous lymphoma	Skin biopsy, blood count, eosinophil count, liver-function tests
Drug-induced vasculitis	†	1-3 wk	Infection, rheumatic diseases, lymphomas	Antinuclear antibodies, rheumatoid factor
Serum sickness or reactions resembling serum sickness	Intravenous proteins, β-lactam antibiotics	8-14 days	Infection	C3 and C4 complement
Anticoagulant-induced necrosis	Warfarin	3-5 days	Disseminated intravascular coagulopathy, septicemia	Protein C deficiency
Angioedema	Heparin Penicillin, cephalosporins, contrast medium, glafenine, ‡ drugs used in anesthesia Nonsteroidal antiinflammatory drugs ACE inhibitors	5-10 days A few minutes to a few hours 1-7 days <4 wk	Insect stings, foods	Platelet count Specific IgE antibodies for penicillin allergy

*See Table 4 for a complete list.

†See Table 5 for a complete list.

‡Glafenine is no longer marketed.



Figure 2. Typical Target Lesions of Erythema Multiforme Major. This case was classified as erythema multiforme major because of associated mucous-membrane lesions. These target lesions include three zones: an erythematous or dusky small central papule that may blister, a raised edematous middle ring, and an erythematous outer ring.

and conjunctiva often occur. Keratitis and corneal erosions are less frequent. Fever is usually higher in toxic epidermal necrolysis (temperature, $>38^{\circ}\text{C}$) than in Stevens-Johnson syndrome, and asthenia, skin pain, and anxiety are often extreme.

The complications of toxic epidermal necrolysis and extensive thermal burns are similar. The severity is proportional to the extent of skin necrosis. Massive transepidermal fluid losses (3 to 4 liters daily in adults with half their body-surface area involved) occur with associated electrolyte imbalance.¹⁸ Prerenal azotemia is common. Bacterial colonization of the skin and decreased immune responsiveness increase the likelihood of sepsis. A hypercatabolic state, sometimes with inhibition of insulin secretion or insulin resistance, is common. Diffuse interstitial pneumonitis, which may lead to the adult respiratory distress syndrome, sometimes develops.

Even if the diagnosis of Stevens-Johnson syndrome or toxic epidermal necrolysis is clinically evident, a skin biopsy helps confirm the diagnosis, thus usually excluding bullous diseases not related to drug therapy. Early on, there is full-thickness epidermal necrosis and detachment, with an only slightly altered underlying dermis (Fig. 6). The use of frozen sections allows a rapid diagnosis. Immunofluorescence studies only help exclude other bullous diseases. Anemia and lymphopenia are frequent, but eosinophilia is rare. Neutropenia suggests a poor prognosis.³²

The regrowth of epidermis may begin within days but usually takes about three weeks, the typical length of the hospitalization.³³ Areas subject to pressure and periorificial areas often heal last. Ocular sequelae affect about 35 percent of patients who survive toxic epidermal necrolysis and a smaller percentage of those with Stevens-Johnson syndrome.^{18,30} A Sjögren-



Figure 3. Dusky or Purpuric Macules Typical of Stevens-Johnson Syndrome.

These lesions may develop an overlying blister. They do not have the three zones of typical target lesions (shown in Fig. 2) and generally are irregularly shaped and vary in size.



Figure 4. Widespread Lesions Characteristic of Stevens-Johnson Syndrome.

The lesions are most heavily concentrated on the trunk and proximal extremities. The darker areas are sites of epidermal necrosis.



Figure 5. Purpuric Macules Typical of Stevens-Johnson Syndrome.

The macules may coalesce to form blisters.

like sicca syndrome with a deficiency of mucin in tears, intumed eyelashes, proliferation of squamous metaplasia, and neovascularization of conjunctiva and cornea, symblepharon, punctate keratitis, and corneal scarring may develop.³⁰ Persistent photophobia, burning eyes, visual impairment, and even blindness may result. Other possible sequelae include scarring, irregular pigmentation, eruptive nevi, persistent erosions of the mucous membranes, phimosis, vaginal synechiae, and abnormal regrowth of nails.¹⁸

Differential Diagnosis

Skin disorders involving desquamation, exfoliation, or blistering are sometimes misdiagnosed as Stevens-Johnson syndrome or toxic epidermal necrolysis. Exfoliative dermatitis is characterized by generalized



Figure 6. Cross Section of Epidermis and Upper Dermis of Normal Human Skin.

The number 1 denotes stratum corneum, 2 stratum granulosum, 3 stratum spinosum, 4 basal cells, and 5 dermis. In toxic epidermal necrolysis, the necrosis of cells from the basal layer and stratum spinosum results in detachment of the epidermis from the dermis. Exfoliative dermatitis is characterized by increased thickness of the stratum corneum. In staphylococcal scalded skin syndrome and exanthematous pustulosis, detachment occurs between the stratum granulosum and the stratum corneum or within the stratum granulosum (hematoxylin and eosin, $\times 400$).



Figure 7. Necrolysis of Skin in Toxic Epidermal Necrolysis. Varying degrees of erythema are seen. The wrinkled areas represent full-thickness necrosis of the epidermis. This dead skin will be lost, resulting in superficial skin ulcers.



Figure 8. Ulcerations and Erythema of the Oral Mucous Membranes and Lips Caused by Toxic Epidermal Necrolysis. These findings can also be seen with erythema multiforme major, Stevens-Johnson syndrome, and primary bullous diseases such as pemphigus vulgaris.

erythema and scaling (Fig. 9).³⁴ When the scales separate in large sheets, especially on the palms and soles, desquamation may be clinically confused with full-thickness epidermal detachment (Fig. 10).

In infants, staphylococcal scalded skin syndrome may resemble toxic epidermal necrolysis. Specific staphylococcal exotoxins cause extensive subcorneal separation of the stratum corneum (Fig. 6 and 11).³⁵ Acute exanthematous pustulosis is drug-induced and resembles pustular psoriasis.³⁶ The subcorneal aseptic pustules are usually distinctive and may coalesce to produce extensive superficial exfoliation (Fig. 12). The mucous membranes are infrequently involved. Subcorneal skin separation (Fig. 6) and the absence of necrosis in both conditions facilitate their pathological and clinical diagnosis.

Paraneoplastic pemphigus of acute onset may be confused with toxic epidermal necrolysis.³⁷ Direct im-




Figure 9. Exfoliative Dermatitis.

There is widespread, scaling, brawny erythema and desquamation.

munofluorescence microscopy can be used to distinguish these disorders. Thermal burns, phototoxic reactions, and pressure blisters occurring in comatose patients may resemble toxic epidermal necrolysis, even on pathological analysis. The pattern of the blisters and the clinical history facilitate proper diagnosis.

Epidemiologic Features

Although infrequent, toxic epidermal necrolysis and Stevens-Johnson syndrome occur in all ages, all races, and both sexes, with an incidence ranging from 0.4 to 1.2 and 1.2 to 6 per million person-years, respectively.^{1,3,19,38-40}

Most cases of toxic epidermal necrolysis are drug-induced. Fewer than 5 percent of patients report no drug use.^{3,19} A strong association with specific medications is observed in about 80 percent of the cases. Other occasional reported causes include chemicals, mycoplasma pneumonia, viral infections, and immunization.^{41,42} That there is a less frequent clear-cut relation of drugs to Stevens-Johnson syndrome (in

about 50 percent of cases) probably reflects the common confusion between this syndrome (Fig. 3 and 4) and erythema multiforme major (Fig. 2).

Drug-induced Stevens-Johnson syndrome and toxic epidermal necrolysis typically begin one to three weeks after the initiation of therapy but occur more rapidly with rechallenge.¹⁸ More than 100 different compounds have been implicated in both syndromes.^{3,18,19,33,38-40,42,43} Table 4 lists frequently implicated drugs. For all drugs, the reported reaction rates are relatively low. The drugs with the highest estimated incidence include co-trimoxazole (trimethoprim-sulfamethoxazole; 1 to 3 reactions per 100,000 users),^{3,39,40} a long-acting combination of sulfadoxine and pyrimethamine (Fansidar-R; 10 reactions per 100,000 users),^{4,23,44} and carbamazepine (14 reactions per 100,000 users).⁴⁵ These estimates, which were based on retrospective series or spontaneous reports, may substantially underestimate the true incidence.

Patients often have underlying diseases. A role for infection as a cofactor has been postulated, but there is little supporting evidence.⁴³ Conditions that alter immunologic function, including systemic lupus erythematosus, may increase risk.⁴⁶ The HLA phenotype B12 is associated with a threefold increase in risk.⁴⁷

Toxic epidermal necrolysis has been described in an animal model of cutaneous acute graft-versus-host disease (GVHD).⁴⁸ Toxic epidermal necrolysis has developed in humans a few weeks after bone marrow transplantation.^{49,50} In transplant recipients cutaneous necrolysis is most often related to acute GVHD, but in some cases it is drug-induced.^{50,51} Ocular lesions are rare in acute GVHD and frequent in drug-induced toxic epidermal necrolysis.^{18,50,51} Whether drug-induced or related to acute GVHD, epidermal necrolysis after bone marrow transplantation suggests a very poor prognosis.⁴⁹⁻⁵¹



Figure 10. Superficial Blisters of the Feet Consisting of Sheets of the Upper Epidermis in a Patient with a Severe Morbilliform Eruption.

This kind of desquamation, especially on the palms and soles, should not be confused with the true full-thickness necrosis of toxic epidermal necrolysis and Stevens-Johnson syndrome.

Patients with the acquired immunodeficiency syndrome have a higher incidence of many drug-induced skin rashes, including Stevens–Johnson syndrome and toxic epidermal necrolysis, with a combined incidence of 1 per 1000 person-years.⁵²⁻⁵⁵ Sulfonamides are the most frequently implicated agent. The risk of reactions to sulfonamides is 10 to 100 times higher among persons infected with the human immunodeficiency virus (HIV) than among other persons. This high risk reflects more frequent drug use and greater susceptibility.^{54,55}

Pathophysiology

Patients with Stevens–Johnson syndrome or toxic epidermal necrolysis induced by sulfonamides or anti-convulsant agents often have an alteration in the detoxification of reactive drug metabolites.^{56,57} The recurrence of Stevens–Johnson syndrome and toxic epidermal necrolysis within 48 hours of rechallenge (although the initial reaction occurs about 14 days after treatment is begun) argues against a di-




Figure 11. Staphylococcal Scalded Skin Syndrome.

The patient has typical periorificial erythema and crusting, as well as superficial peeling and erosions of the upper epidermis with indistinct underlying erythema. The clinical picture is similar to that seen with a superficial thermal scalding.



Figure 12. Acute Exanthematous Pustulosis.

Small pustules are seen on erythematous skin. Confluent pustules may produce superficial erosions and sometimes blisters.

rect toxic effect and is more consistent with immunologic mechanisms.¹⁸

The immunopathologic pattern of early lesions suggests a cell-mediated cytotoxic reaction against epidermal cells.⁵⁸⁻⁶¹ The epidermis is infiltrated by activated lymphocytes, mainly CD8 cells, and macrophages.⁵⁸⁻⁶¹ An immune reaction against drug-reactive metabolites produced in excess may be responsible. Because infiltrating cells are present in only moderate numbers, it is unlikely that these cells are the principal cause of epidermal necrosis. Cytokines, released by activated mononuclear cells and keratinocytes, may contribute to local cell death, fever, and malaise.

Prognosis and Treatment

Mortality rates are below 5 percent for Stevens–Johnson syndrome but about 30 percent for toxic epidermal necrolysis.^{18,19} Sepsis is the principal cause of death. More extensive epidermal detachment, increased age, increased blood urea nitrogen concentrations, and visceral involvement indicate a poorer prognosis. The prognosis does not appear to be affected by the type and dose of the responsible drug or the presence of HIV infection.

The physician is responsible for the early recognition of the reaction, the withdrawal of all potentially responsible drugs, and the initiation of intravenous-fluid replacement. Although some drugs are clearly more often responsible than others (Table 4), all drugs, especially those introduced within one month of the reaction, should be considered suspect. Patients with widespread skin involvement should be transferred to an intensive care unit or burn unit. During transfer, pain control, fluid replacement, aseptic handling, and avoidance of any adhesive material are important. The main principles of therapy are the same as for thermal burns, including aggressive fluid replacement, nutritional support, and antibacterial treatment.^{62,63}

Table 4. Drugs Associated with Stevens-Johnson Syndrome and Toxic Epidermal Necrolysis.

DRUGS MOST FREQUENTLY ASSOCIATED*	DRUGS ALSO ASSOCIATED
Sulfadoxine	Cephalosporins
Sulfadiazine	Fluoroquinolones
Sulfasalazine	Vancomycin
Co-trimoxazole	Rifampin
Hydantoin	Ethambutol
Carbamazepine	Fenbufen
Barbiturates	Tenoxicam
Benoxaprofen†	Tiaprofenic acid
Phenylbutazone	Diclofenac
Isoxicam†	Sulindac
Piroxicam	Ibuprofen
Chlormezanone	Ketoprofen
Allopurinol	Naproxen
Amithiozone	Thiabendazole
Aminopenicillins	

*Together these drugs account for approximately two thirds of the cases attributed to drugs in large series in France, Germany, and the United States.^{1,3,19,31,43}

†This drug is no longer marketed.

Many interventions meant to halt the progression of toxic epidermal necrolysis have been tried, each in a few patients. A positive result, usually defined as one that halts the spread of necrolysis, has typically been noted after several previous "ineffective" treatments. However, in untreated patients, the average duration of progression is less than four days. Therefore, the results of these uncontrolled studies cannot be interpreted. Short courses of corticosteroids early in the disease have been advocated,⁶⁴ but their effectiveness has never been demonstrated in controlled trials. Toxic epidermal necrolysis can develop in patients who are receiving high-dose corticosteroids.^{3,65} Retrospective studies demonstrate no benefit of corticosteroids or higher rates of morbidity and mortality in corticosteroid-treated patients.⁶⁶⁻⁶⁸ We recommend against their use. Case reports claiming that plasmapheresis, cyclosporine, cyclophosphamide, and monoclonal antibodies directed against cytokines are helpful should be regarded with skepticism.^{59,69,70}

Because these disorders progress so rapidly, many cases have evolved fully before the patients are hospitalized, thus limiting the practical value of such treatments. Therefore, therapies that reduce morbidity associated with skin loss or accelerate regrowth of the skin are the most promising.

HYPERSENSITIVITY SYNDROME

A variety of hypersensitivity responses are responsible for most cutaneous reactions to drugs. The term "hypersensitivity syndrome" refers to a specific severe idiosyncratic reaction. The syndrome typically includes skin rash and fever, often with hepatitis, arthralgias, lymphadenopathy, or hematologic abnor-

malities (Tables 1, 2, and 3). Perhaps because of its relatively late onset, slow evolution, and clinical similarity to many infectious illnesses, the diagnosis of hypersensitivity syndrome may be delayed.

The aromatic antiepileptic agents (phenytoin, carbamazepine, and phenobarbital) — with an estimated incidence of 1 reaction per 5000 patients and perhaps a higher rate among black patients — and sulfonamides are the most frequent causes of hypersensitivity syndrome.^{56,57,71-76} Other drugs, especially allopurinol, gold salts, dapsone, and sorbinil, are also associated with the syndrome.⁷⁷⁻⁸⁰ Hypersensitivity syndrome may be difficult to distinguish from serum sickness or drug-induced vasculitis. Laboratory findings often help distinguish these clinically similar conditions from each other and from infectious diseases (Table 2).

The hypersensitivity syndrome typically develops two to six weeks after a drug is first used, later than most other serious skin reactions (Table 3). With antiepileptic drugs, fever and rash are the most frequent presenting symptoms (in 87 percent of cases). Lymphadenopathy (in about 75 percent) is frequent and usually due to benign lymphoid hyperplasia.¹⁷ Atypical lymphoid hyperplasia and pseudolymphoma occasionally occur.⁸¹ Some of these cases resolve with withdrawal of the drug, but in some cases lymphoma eventually develops.⁸² Hepatitis (51 percent); interstitial nephritis (11 percent); hematologic abnormalities, especially eosinophilia (30 percent); and mononucleosis-like atypical lymphocytosis are also common.¹⁷ Involvement of the heart, lung, thyroid, and brain is less frequent.^{17,83} Severe cases of hepatitis may be life-threatening.⁸⁴

A genetically determined inability to detoxify the toxic arene oxide metabolic products of anticonvulsant agents has been observed in patients with the hypersensitivity syndrome, but the syndrome also occurs in patients without this abnormality.^{17,85} Cells from the parents of affected patients have a degree of in vitro sensitivity to these toxic metabolites that is intermediate between that of affected patients and that of controls.¹⁷ Positive tests have been noted in multiple family members.⁸⁶ Cross-sensitivity between the various aromatic antiepileptic drugs is well documented, making it difficult to select alternative anticonvulsant therapy.^{87,88}

Rashes of all types are reported with carbamazepine or phenytoin therapy.^{73,89} Most of these rashes are morbilliform (Fig. 1) and will abate even if the drug is continued. Unfortunately, the hypersensitivity syndrome often initially presents as a morbilliform eruption indistinguishable from less serious reactions (Fig. 1). The reaction may become indurated and infiltrated (Fig. 13). Any cutaneous reaction associated with aromatic anticonvulsant agents that includes facial swelling, exfoliative dermatitis (Fig. 9), fever, lymphadenopathy, eosinophilia, arthritis, hepatitis, or bullous or purpuric skin lesions



Figure 13. Infiltrative Papules Coalescing into Plaques.

These papules are typical of the more advanced eruptions seen in the hypersensitivity syndrome associated with aromatic antiepileptic drugs. The histologic appearance of these indurated confluent papules and plaques is often similar to that of early stages of cutaneous T-cell lymphoma.

or begins more than two weeks after therapy is initiated is especially worrisome.

Sulfonamide-induced hypersensitivity syndrome and that induced by antiepileptic agents are clinically indistinguishable.^{16,57} Slow *N*-acetylation of sulfonamide and increased susceptibility of patients' leukocytes in vitro to toxic hydroxylamine metabolites are associated with greater susceptibility, but only a small percentage of people who acetylate sulfonamides slowly have reactions to these drugs.^{16,57,90}

Recovery is usually total, but rash and hepatitis may persist for weeks. Treatment with corticosteroids has been widely advocated, but controlled studies are lacking.⁹¹ We have observed dramatic improvements in symptoms and laboratory measurements in patients given systemic corticosteroids (≥ 0.5 mg per kilogram of body weight). Relapses of rash and hepatitis may occur as corticosteroids are tapered. Transient hypothyroidism may also develop.⁹²

VASCULITIS AND SERUM SICKNESS

Vasculitis characterized by inflammation and necrosis of blood-vessel walls has many causes.⁹³ Drug-induced vasculitis typically involves small vessels and is a subtype of hypersensitivity vasculitis,⁹⁴ which also includes cutaneous leukocytoclastic vasculitis and serum sickness.⁹⁴

In 1905, von Pirquet and Schick described serum sickness in children treated with horse serum containing diphtheria antitoxin.⁹⁵ More recently, serum sickness has been noted in patients treated with horse antithymocyte globulins or human diploid-cell rabies vaccine.⁹⁵⁻⁹⁷ Serum sickness is a type III hypersensitivity reaction mediated by the deposition of immune complexes in small vessels, activation of complement, and recruitment of granulocytes. Drug-induced vasculitis is believed to result from antibodies directed against drug-related haptens, but this has not been

proved.⁹⁸ Alternative proposed mechanisms include direct drug toxicity against vessel walls, autoantibodies reacting with endothelial cells, and cell-mediated cytotoxic reactions against vessels.^{93,99-101}

Clinical Presentation

Serum sickness has distinctive skin findings. Typically, erythema first occurs on the sides of the fingers, toes, and hands, before a more widespread eruption that is most often morbilliform (in two thirds of patients), sometimes with urticaria.⁹⁵⁻⁹⁷ Urticaria is seldom seen alone. About half the cases of serum sickness have visceral involvement. Rash, fever, constitutional symptoms, arthralgia, and arthritis are the most frequent clinical findings.^{95,96}

The clinical hallmark of cutaneous vasculitis is palpable purpuric papules, classically located on the lower extremities, although any site may be involved (Fig. 14).^{93,102,103} Hemorrhagic blisters, urticaria, ulcers, nodules, Raynaud's disease, and digital necrosis may also occur. The same vasculitic process may also affect the kidney, liver, gastrointestinal tract, or nervous system and can be life-threatening. Histologically, small dermal vessels exhibit fibrinoid necrosis, infiltration by polymorphonuclear leukocytes, and nuclear dust.¹⁰³ The results of direct immunofluorescence are often positive, with deposits of IgM and C3 complement on capillary walls.¹⁰³

In serum sickness, serum C3 and C4 complement levels are markedly decreased.⁹⁶ Serum sickness begins 8 to 14 days after the initial exposure to a foreign protein. Other kinds of drug-induced vasculitis typically develop 7 to 21 days after a new drug is begun, but the interval can be longer.⁹⁹ When otherwise unexplained palpable purpura develops in a patient, any drug the patient is taking, especially those introduced within the preceding two months, should be considered suspect. Withdrawing the drug usually leads to rapid resolution. Systemic corticosteroids may benefit some patients.

Differential Diagnosis

Drug-induced hypersensitivity vasculitis may be difficult to distinguish from other types of vasculitis. Schönlein-Henoch purpura usually occurs in younger patients, with characteristic large purpuric cutaneous lesions, often on the buttocks. Renal and gastrointestinal involvement is common. IgA is deposited in vessels.¹⁰⁴ Cryoglobulinemia-associated vasculitis has a chronic or recurrent course. Polyarteritis nodosa and Wegener's granulomatosis sometimes begin as a palpable purpura.¹⁰⁵ Most patients with Wegener's granulomatosis have autoantibodies to neutrophil cytoplasmic antigens,¹⁰⁶ a feature that is usually absent in drug-induced vasculitis. Infection and collagen vascular disorders can also induce vasculitis.⁹³ Excluding infection as a cause is often the greatest challenge. Drugs cause about 10 percent of cases of acute cutaneous vasculitis.^{102,103}

Only a small fraction of drug reactions take the



Figure 14. Drug-Induced Vasculitis Presenting as Palpable Purpuric Papules and Plaques, Occasionally with Overlying Small Blisters, Especially on the Lower Extremities.

form of vasculitis.^{7,8} Propylthiouracil may induce a clinically distinctive vasculitis initially involving the face and ear lobes, with erythema and later purpura.^{107,108} Antinuclear antibodies and antineutrophil cytoplasmic antibodies may be produced.^{109,110}

Table 5 lists drugs that are often implicated in causing vasculitis. Recently reported drugs associated with vasculitis include the retinoids and quinolones and agents used in immunotherapy.¹¹¹⁻¹¹³

Reactions resembling serum sickness (rash, fever, and arthralgias) occur in about 1 of 2000 children given cefaclor and have also been reported with minocycline, penicillins, propranolol, streptokinase, and other drugs.¹¹⁴⁻¹¹⁸ Since reduced concentrations of serum complement are not generally noted, most such cases probably do not represent true serum sickness.

ANTICOAGULANT-INDUCED SKIN NECROSIS

A rare and devastating effect of warfarin therapy is skin necrosis, a consequence of occlusive thrombi in vessels of the skin and subcutaneous tissue.¹¹⁹ Typically, warfarin-induced skin necrosis begins three to five days after therapy is initiated. The use of higher initial doses, obesity, and female sex appear to increase the risk.¹²⁰ Red, painful plaques evolve to ne-

erosis (Fig. 15), with hemorrhagic blisters or necrotic scars, frequently in areas with large quantities of adipose tissue, including the breasts, hips, and buttocks. Acral involvement is infrequent.

People with hereditary deficiency of protein C, a natural anticoagulant protein, are at highest risk, even if they are heterozygotes and thus have no history of recurrent thrombosis.¹¹⁹⁻¹²² In these persons, warfarin greatly depresses protein C levels before decreasing other vitamin K-dependent coagulation factors, inducing a transient hypercoagulable state and thrombus formation.¹¹⁹ Rapid recognition of painful, red plaques in fatty areas is the key to diagnosis. Therapy includes discontinuing warfarin, administering vitamin K to reverse the effect of warfarin, giving heparin as an anticoagulant, and administering monoclonal antibody-purified protein C concentrate.¹²³ Necrotic tissues may require surgical débridement and grafting. If not rapidly treated, this condition may be fatal. It develops in 1 in 10,000 patients receiving warfarin, a prevalence that is about 2 percent of the estimated prevalence of protein C deficiency.^{119,124} Since most persons with protein C deficiency tolerate warfarin, other factors must play a part. Protein S or antithrombin III deficiency also confers an increased risk.¹²⁵

Heparin can also cause thrombosis and necrosis in the skin and other organs.¹²⁶ The mechanisms of heparin-induced and warfarin-induced necrosis are almost certainly different. Heparin can induce vessel thrombosis with fibrin thrombi at injection sites and distant skin sites and in other organs.^{127,128} Localized reactions at injection sites are frequent, but devastating widespread reactions are not. Heparin-induced platelet aggregation may be responsible for widespread reactions. These lesions need to be differentiated from other cutaneous reactions to heparin at injection sites, which are most likely immunologic.^{126,127} Neither pro-

Table 5. Agents Most Often Associated with Vasculitis, Serum Sickness, and Reactions Resembling Serum Sickness.

Vasculitis
Allopurinol
Penicillin
Aminopenicillins
Sulfonamides
Thiazides
Pyrazolones
Hydantoins
Propylthiouracil
Raynaud's disease or digital necrosis
Beta-blockers
Ergot alkaloids
Bleomycin
Serum sickness
Serum preparations
Vaccines
Reactions resembling serum sickness
Beta-blockers
Streptokinase
β -Lactam antibiotics

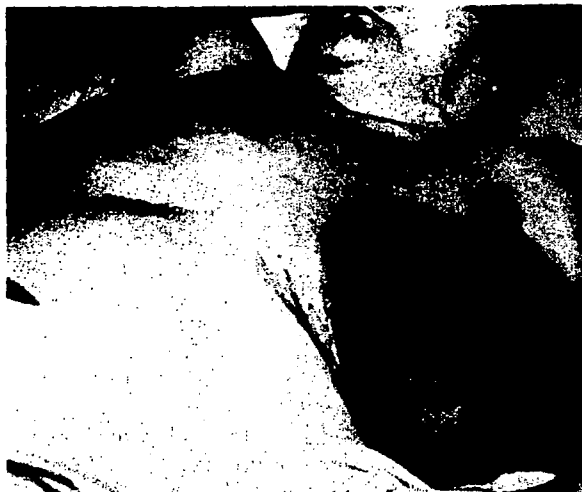

Figure 15. Warfarin-Induced Necrosis.

In this woman, painful erythema and induration of the breasts were followed by necrosis of these fatty areas.

tein C nor protein S plays a part. In heparin-induced necrosis, levels of fibrinogen and fibrin-split products are usually normal, but platelet counts are often depressed.¹²⁶ Evidence of primary vasculitis is lacking. Heparin-induced thrombocytopenia and thrombosis may be an immune-complex disorder.¹²⁹ In addition to discontinuation of the drug, treatment with warfarin or antiplatelet drugs is useful.¹²⁶

ANGIOEDEMA

Immediate-hypersensitivity reactions can produce a range of cutaneous findings from simple urticaria to angioedema or anaphylaxis. The mechanism and treatment of IgE-mediated immediate-hypersensitivity reactions including anaphylaxis, which are most often induced by insect stings and food, have been reviewed recently.^{130,131} Many drug-induced cases of angioedema are not mediated by IgE. We shall briefly discuss newer drugs that cause angioedema or anaphylaxis.

Antibiotics (especially the penicillins), anesthetics, and radiocontrast agents are the most common causes of serious IgE-mediated, drug-induced immediate hypersensitivity.^{130,131} Angioedema occurs in about 1 per 10,000 courses of penicillin and leads to death in 1 to 5 per 100,000 courses. In persons receiving long-term penicillin prophylaxis for rheumatic fever, the risk of angioedema persists during treatment.¹³²

Other frequently used drugs, including angiotensin-converting-enzyme (ACE) inhibitors, nonsteroidal antiinflammatory drugs, radiocontrast agents, opiates, and curare, cause angioedema that is not IgE-mediated. ACE inhibitors induce the majority of cases of angioedema that lead to hospitalization.^{133,134} The observed incidence of drug-related angioedema has increased in parallel with the increased use of ACE inhibitors, especially longer-acting ACE inhibitors.¹³³⁻¹³⁶ Angioedema occurs in 2 to 10 per 10,000

new users of ACE inhibitors — a rate that is probably higher than that associated with penicillins.¹³⁷ The risk is highest during the first three weeks of therapy.¹³⁷ These reactions may be due to the inhibition of kinin metabolism.¹³⁸ Hemodialysis with high-flux dialysis membranes, which may increase the production of bradykinin, greatly increases the risk of anaphylactoid reactions associated with ACE inhibitors.¹³⁹⁻¹⁴¹ Reactions occur in up to 35 percent of patients treated in this manner.¹⁴¹

CONCLUSIONS

Adverse reactions to drugs most often affect the skin, but only a small fraction are life-threatening or lead to disabling sequelae. Because of the low frequency of such severe reactions (usually less than 1 reaction per 5000 exposed patients), they are unlikely to be detected in premarketing clinical trials. Only if clinicians recognize and report severe reactions to regulatory authorities and manufacturers can new drugs associated with a high risk of such reactions be identified, relabeled, or withdrawn from the market.^{142,143}

For many severe cutaneous reactions to drugs, including toxic epidermal necrolysis, Stevens-Johnson syndrome, vasculitis, and serum sickness, medical intervention is limited to the early recognition of the symptoms and the withdrawal of the offending drug. Even for other reactions that may benefit from therapy, early recognition of the symptoms and prompt withdrawal of suspect drugs are usually the most important steps. Therefore, clinicians should carefully evaluate the signs and symptoms of all adverse cutaneous reactions thought to be due to drugs and immediately discontinue all drugs that are not essential, especially when the signs or symptoms associated with more severe reactions are present (Table 2). After recovery, patients should be advised to avoid the drug thought to be responsible for the reaction and all chemically related compounds. Patients with toxic epidermal necrolysis and hypersensitivity syndrome should alert their first-degree relatives to their elevated risk of such reactions to the same drugs.

REFERENCES

- Chan HL, Stern RS, Arndt KA, et al. The incidence of erythema multiforme, Stevens-Johnson syndrome, and toxic epidermal necrolysis: a population-based study with particular reference to reactions caused by drugs among outpatients. *Arch Dermatol* 1990;126:43-7.
- Corre KA, Spielberg TE. Adverse drug reaction processing in the United States and its dependence on physician reporting: zomepirac (Zomax) as a case in point. *Ann Emerg Med* 1988;17:145-9.
- Roujeau JC, Guillaume JC, Febré JP, Penso D, Flechet ML, Girre JP. Toxic epidermal necrolysis (Lyell syndrome): incidence and drug etiology in France, 1981-1985. *Arch Dermatol* 1990;126:37-42.
- Miller KD, Lobel HO, Satriale RF, Kuritsky JN, Stern R, Campbell CC. Severe cutaneous reactions among American travelers using pyrimethamine-sulfadoxine (Fansidar) for malaria prophylaxis. *Am J Trop Med Hyg* 1986;35:451-8.
- Bigby M, Jick S, Jick H, Arndt K. Drug-induced cutaneous reactions: a report from the Boston Collaborative Drug Surveillance Program on 15,438 consecutive inpatients, 1975 to 1982. *JAMA* 1986;256:3358-63.
- Leape LL, Brennan TA, Laird N, et al. The nature of adverse events in hospitalized patients. results of the Harvard Medical Practice Study II. *N Engl J Med* 1991;324:377-84.

7. Alanko K, Stubb S, Kauppinen K. Cutaneous drug reactions: clinical types and causative agents: a five-year survey of in-patients (1981-1985). *Acta Derm Venereol (Stockh)* 1989;69:223-6.
8. Ives TJ, Bentz EJ, Gwyther RE. Dermatologic adverse drug reactions in a family medicine setting. *Arch Fam Med* 1992;1:241-5.
9. Varga J, Vitto J, Jimenez SA. The cause and pathogenesis of the eosinophilia-myalgia syndrome. *Ann Intern Med* 1992;116:140-7.
10. Kramer MS, Leventhal JM, Hutchinson TA, Feinstein AR. An algorithm for the operational assessment of adverse drug reactions. I. Background, description, and instructions for use. *JAMA* 1979;242:623-32.
11. Turner WM. The Food and Drug Administration algorithm: special workshop — regulatory. *Drug Inf J* 1984;18:259-66.
12. Louik C, Lacouture PG, Mitchell AA, et al. A study of adverse reaction algorithms in a drug surveillance program. *Clin Pharmacol Ther* 1985;38:183-7.
13. Ressler C, Mendelson LM. Skin test for diagnosis of penicillin allergy — current status. *Ann Allergy* 1987;59:167-70.
14. Bruynzeel D, van Ketel W. Skin tests in the diagnosis of maculo-papular drug eruptions. *Semin Dermatol* 1987;6:119-24.
15. Shear NH. Diagnosing cutaneous adverse reactions to drugs. *Arch Dermatol* 1990;126:94-7.
16. Rieder MJ, Utrecht J, Shear NH, Cannon M, Miller M, Spielberg SP. Diagnosis of sulfonamide hypersensitivity reactions by in-vitro "rechallenge" with hydroxylamine metabolites. *Ann Intern Med* 1989;110:286-9.
17. Shear NH, Spielberg SP. Anticonvulsant hypersensitivity syndrome: in vitro assessment of risk. *J Clin Invest* 1988;82:1826-32.
18. Revuz J, Penso D, Roujeau JC, et al. Toxic epidermal necrolysis: clinical findings and prognosis factors-in-87-patients. *Arch Dermatol* 1987;123:1160-5.
19. Schöpf E, Stühmer A, Rzany B, Victor N, Zentgraf R, Kapp JF. Toxic epidermal necrolysis and Stevens-Johnson syndrome: an epidemiologic study from West Germany. *Arch Dermatol* 1991;127:839-42.
20. Bastuji-Garin S, Rzany B, Stern RS, Shear NH, Naldi L, Roujeau JC. Clinical classification of cases of toxic epidermal necrolysis, Stevens-Johnson syndrome, and erythema multiforme. *Arch Dermatol* 1993;129:92-6.
21. Stevens AM, Johnson FC. A new eruptive fever associated with stomatitis and ophthalmia: report of two cases in children. *Am J Dis Child* 1922;24:526-33.
22. Lyell A. Toxic epidermal necrolysis: an eruption resembling scalding of the skin. *Br J Dermatol* 1956;68:355-61.
23. Bergoend H, Löffler A, Amar R, Maleville J. Réactions cutanées survenues au cours de la prophylaxie de masse de la méningite cérébro-spinale par un sulfamide long-retard (à propos de 997 cas). *Ann Dermatol Syphiligr (Paris)* 1968;95:481-90.
24. Ruiz-Maldonado R. Acute disseminated epidermal necrosis types 1, 2, and 3: study of sixty cases. *J Am Acad Dermatol* 1985;13:623-35.
25. Huff JC, Weston WL, Tonnesen MG. Erythema multiforme: a critical review of characteristics, diagnostic criteria, and causes. *J Am Acad Dermatol* 1983;8:763-75.
26. Roupe G, Ahlmen M, Fagerberg B, Suurkula M. Toxic epidermal necrolysis with extensive mucosal erosions of the gastrointestinal and respiratory tracts. *Int Arch Allergy Appl Immunol* 1986;80:145-51.
27. Timsit JF, Mion G, Rouyer N, Le Gulluche Y, Carsin H. Bronchopulmonary distress associated with toxic epidermal necrolysis. *Intensive Care Med* 1992;18:42-4.
28. Chosidow O, Delchier J-C, Chaumette MT, et al. Intestinal involvement in drug-induced toxic epidermal necrolysis. *Lancet* 1991;337:928.
29. Wilkins J, Morrison L, White CR Jr. Oculocutaneous manifestations of the erythema multiforme/Stevens-Johnson/toxic epidermal necrolysis spectrum. *Dermatol Clin* 1992;10:571-82.
30. Binaghi M, Kosos M, Saiaq P, Roujeau JC, Coscas G. Atteinte oculaire au cours du syndrome de Lyell: incidence, évolution, pronostic. *Ophthalmologie* 1988;2:121-2.
31. Prendiville JS, Hebert AA, Greenwald MJ, Esterly NB. Management of Stevens-Johnson syndrome and toxic epidermal necrolysis in children. *J Pediatr* 1989;115:881-7.
32. Westly ED, Wechsler HL. Toxic epidermal necrolysis: granulocytic leukopenia as a prognostic indicator. *Arch Dermatol* 1984;120:721-6.
33. Jordan MH, Lewis MS, Jeng JG, Rees JM. Treatment of toxic epidermal necrolysis by burn units: another market or another threat? *J Burn Care Rehabil* 1991;12:579-81.
34. Marks J. Erythroderma and its management. *Clin Exp Dermatol* 1982;7:415-22.
35. Melish ME, Glasgow LA. The staphylococcal scalded-skin syndrome: development of an experimental model. *N Engl J Med* 1970;282:1114-9.
36. Roujeau JC, Bioulac-Sage P, Bourseau C, et al. Acute generalized exanthematous pustulosis: analysis of 63 cases. *Arch Dermatol* 1991;127:1333-8.
37. Mutasim DF, Pelc NJ, Anhalt GJ. Paraneoplastic pemphigus. *Dermatol Clin* 1993;11:473-81.
38. Bottiger LE, Strandberg I, Westerholm B. Drug-induced febrile mucocutaneous syndrome with a survey of the literature. *Acta Med Scand* 1975;198:229-33.
39. Naldi L, Locati F, Marchesi I, Cainelli T. Incidence of toxic epidermal necrolysis in Italy. *Arch Dermatol* 1990;126:1103-4.
40. Strom BL, Carson JL, Halpern AC, et al. A population-based study of Stevens-Johnson syndrome: incidence and antecedent drug exposures. *Arch Dermatol* 1991;127:831-8.
41. House RA, Jakubovic H, Wong L, Holness DL. Work-related toxic epidermal necrolysis? *J Occup Med* 1992;34:135-9.
42. Nethercott JR, Choi BC. Erythema multiforme (Stevens-Johnson syndrome) — chart review of 123 hospitalized patients. *Dermatologica* 1985;171:383-96.
43. Stern RS, Chan HL. Usefulness of case report literature in determining drugs responsible for toxic epidermal necrolysis. *J Am Acad Dermatol* 1989;21:317-22.
44. Helligren U, Rombo L, Berg B, Carlson J, Wilholm BE. Adverse reactions to sulphadoxine-pyrimethamine in Swedish travellers: implications for prophylaxis. *BMJ* 1987;295:365-6.
45. Askmark H, Wiholm B-E. Epidemiology of adverse reactions to carbamazepine as seen in a spontaneous reporting system. *Acta Neurol Scand* 1990;81:131-40.
46. Burge SM, Dawber RPR. Stevens-Johnson syndrome and toxic epidermal necrolysis in a patient with systemic lupus erythematosus. *J Am Acad Dermatol* 1985;13:665-6.
47. Roujeau JC, Huynh TN, Braccq C, Guillaume JC, Revuz J, Touraine R. Genetic susceptibility to toxic epidermal necrolysis. *Arch Dermatol* 1987;123:1171-3.
48. Billingham RE, Streilein JW. Toxic epidermal necrolysis and homologous disease in hamsters. *Arch Dermatol* 1968;98:528-39.
49. Peck GL, Elias PM, Graw RG Jr. Graft-versus-host reaction and toxic epidermal necrolysis. *Lancet* 1972;2:1151-3.
50. Villada G, Roujeau JC, Cordonnier C, et al. Toxic epidermal necrolysis after bone marrow transplantation: study of nine cases. *J Am Acad Dermatol* 1990;23:870-5.
51. McDonald BJ, Singer JW, Bianco JA. Toxic epidermal necrolysis possibly linked to aztreonam in bone marrow transplant patients. *Ann Pharmacother* 1992;26:34-5.
52. Coopman SA, Johnson RA, Platt R, Stern RS. Cutaneous disease and drug reactions in HIV infection. *N Engl J Med* 1993;328:1670-4.
53. Porteous DM, Berger TG. Severe cutaneous drug reactions (Stevens-Johnson syndrome and toxic epidermal necrolysis) in human immunodeficiency virus infection. *Arch Dermatol* 1991;127:740-1.
54. Saiaq P, Caumes E, Chosidow O, Revuz J, Roujeau JC. Drug-induced toxic epidermal necrolysis (Lyell syndrome) in patients infected with the human immunodeficiency virus. *J Am Acad Dermatol* 1992;26:567-74.
55. Rzany B, Mockenhaupt M, Stocker U, Hamouda O, Schöpf E. Incidence of Stevens-Johnson syndrome and toxic epidermal necrolysis in patients with the acquired immunodeficiency syndrome in Germany. *Arch Dermatol* 1993;129:1059.
56. Spielberg SP, Gordon GB, Blake DA, Goldstein DA, Herlong HF. Predisposition to phenytoin hepatotoxicity assessed in vitro. *N Engl J Med* 1981;305:722-7.
57. Shear NH, Spielberg SP, Grant DM, Tang BK, Kalow W. Differences in metabolism of sulfonamides predisposing to idiosyncratic toxicity. *Ann Intern Med* 1986;105:179-84.
58. Merot Y, Gravallesse E, Guillen FJ, Murphy GF. Lymphocyte subsets and Langerhans' cells in toxic epidermal necrolysis: report of a case. *Arch Dermatol* 1986;122:455-8.
59. Heng MC, Allen SG. Efficacy of cyclophosphamide in toxic epidermal necrolysis: clinical and pathophysiologic review. *J Am Acad Dermatol* 1991;25:778-86.
60. Villada G, Roujeau JC, Clerici T, Bourgault I, Revuz J. Immunopathology of toxic epidermal necrolysis: keratinocytes, HLA-DR expression, Langerhans cells, and mononuclear cells: an immunopathologic study of five cases. *Arch Dermatol* 1992;128:50-3.
61. Correia O, Delgado L, Ramos JP, Resende C, Torninha JA. Cutaneous T-cell recruitment in toxic epidermal necrolysis: further evidence of CD8+ lymphocyte involvement. *Arch Dermatol* 1993;129:466-8.
62. Heimbach DM, Engrav LH, Marvin JA, Hamar TJ, Grube BJ. Toxic epidermal necrolysis: a step forward in treatment. *JAMA* 1987;257:2171-5. [Erratum. *JAMA* 1987;258:1894.]
63. Demling RH. Burns. *N Engl J Med* 1985;313:1389-98.
64. Sheretz EF, Jegasothy BV, Lazarus GS. Phenytoin hypersensitivity reaction presenting with toxic epidermal necrolysis and severe hepatitis: report of a patient treated with corticosteroid "pulse therapy." *J Am Acad Dermatol* 1985;12:178-81.
65. Rzany B, Schmitt H, Schöpf E. Toxic epidermal necrolysis in patients receiving glucocorticosteroids. *Acta Derm Venereol (Stockh)* 1991;71:171-2.
66. Kim PS, Goldfarb JW, Gaisford JC, Slater H. Stevens-Johnson syndrome and toxic epidermal necrolysis: a pathophysiologic review with recommendations for a treatment protocol. *J Burn Care Rehabil* 1983;4:91-100.
67. Halebian PH, Corder VJ, Madden MR, Finklestein JL, Shires GT. Improved burn center survival of patients with toxic epidermal necrolysis managed without corticosteroids. *Ann Surg* 1986;204:503-12.

55. Weston WL, Oranje AP, Rasmussen JE, et al. Corticosteroids for erythema multiforme. *Pediatr Dermatol* 1989;6:229-50.
56. Kamanabroo D, Schmutz-Landgraf W, Czarnetzki BM. Plasmapheresis in severe drug-induced toxic epidermal necrolysis. *Arch Dermatol* 1985;121:355-9.
57. Ranzito L, Grant-Kels JM, Daman LA. Drug-induced toxic epidermal necrolysis treated with cyclosporin. *Int J Dermatol* 1989;28:441-4.
58. Perekanos J, Camfield P, Camfield C, Gordon K. Allergic rash due to antiepileptic drugs: clinical features and management. *Epilepsia* 1991;32:555-9.
59. Pellock JM. Carbamazepine side effects in children and adults. *Epilepsia* 1987;28 Suppl 3:564-570.
60. Rupp RP, Norton JA, Young B, Tibbs PA. Cutaneous reactions in head-injured patients receiving phenytoin for seizure prophylaxis. *Neurosurgery* 1987;13:272-5.
61. Temkin NR, Dikmen SS, Wilensky AJ, Keihm J, Chabal S, Winn HR. A randomized, double-blind study of phenytoin for the prevention of post-traumatic seizures. *N Engl J Med* 1990;323:497-502.
62. Harada F. Phenytoin hypersensitivity: 38 cases. *Neurology* 1979;29:1480-5.
63. Livingston S, Villamater C, Sakata Y, Pauli LL. Use of carbamazepine in epilepsy: results in 87 patients. *JAMA* 1967;200:204-8.
64. Lupton GP, Odom RB. The allopurinol hypersensitivity syndrome. *J Am Acad Dermatol* 1979;1:365-74.
65. Serre H, Sany J, Rosenberg F. Les effets secondaires de la chrysothérapie. *Ann Med Interne (Paris)* 1976;127:552-9.
66. Tomecki KJ, Catalano CJ. Dapsone hypersensitivity: the sulfone syndrome revisited. *Arch Dermatol* 1981;117:38-9.
67. Spielberg SP, Shear NH, Cannon M, Hutson NJ, Gunderson K. In-vitro assessment of a hypersensitivity syndrome associated with sorbinil. *Ann Intern Med* 1991;114:720-4.
68. Rijlaarsdam U, Scheffer E, Meijer CJ, Kruyswijk MR, Willemze R. Mycosis fungoides-like lesions associated with phenytoin and carbamazepine therapy. *J Am Acad Dermatol* 1991;24:216-20.
69. Rosenthal CJ, Noguera CA, Coppola A, Kapelner SN. Pseudolymphoma with mycosis fungoides manifestations, hyperresponsiveness to diphenylhydantoin, and lymphocyte dysregulation. *Cancer* 1982;49:2305-14.
70. Ray-Chaudhuri K, Pye IF, Boggild M. Hypersensitivity to carbamazepine presenting with a leukemoid reaction, eosinophilia, erythroderma, and renal failure. *Neurology* 1989;39:436-8.
71. Parker WA, Shearer CA. Phenytoin hepatotoxicity: a case report and review. *Neurology* 1979;29:175-8.
72. Maguire JH, Wettrell G, Rane A. Apparently normal phenytoin metabolism in a patient with phenytoin-induced rash and lymphadenopathy. *Br J Clin Pharmacol* 1987;24:554-7.
73. Gennis MA, Vemuri R, Burns EA, Hill JV, Miller MA, Spielberg SP. Familial occurrence of hypersensitivity to phenytoin. *Am J Med* 1991;91:631-4.
74. Beran RG. Cross-reactive skin eruption with both carbamazepine and oxcarbazepine. *Epilepsia* 1993;34:163-5.
75. Pirmohamed M, Graham A, Roberts P, et al. Carbamazepine-hypersensitivity: assessment of clinical and in vitro chemical cross-reactivity with phenytoin and oxcarbazepine. *Br J Clin Pharmacol* 1991;32:741-9.
76. Wilson JT, Hojer B, Tomson G, Rane A, Sjoqvist F. High incidence of a concentration-dependent skin reaction in children treated with phenytoin. *BMJ* 1978;1:1583-6.
77. Rieder MJ, Shear NH, Kanee A, Tang BK, Spielberg SP. Prominence of slow acetylator phenotype among patients with sulfonamide hypersensitivity reactions. *Clin Pharmacol Ther* 1991;49:13-7.
78. Murphy JM, Mashman J, Miller JD, Bell JB. Suppression of carbamazepine-induced rash with prednisone. *Neurology* 1991;41:144-5.
79. Gupta A, Eggo MC, Utrecht JP, et al. Drug-induced hypothyroidism: the thyroid as a target organ in hypersensitivity reactions to anticonvulsants and sulfonamides. *Clin Pharmacol Ther* 1992;51:56-67.
80. Fauci AS, Haynes B, Katz P. The spectrum of vasculitis: clinical, pathologic, immunologic and therapeutic considerations. *Ann Intern Med* 1978;89:600-76.
81. Calabrese LH, Michel BA, Bloch DA, et al. The American College of Rheumatology 1990 criteria for the classification of hypersensitivity vasculitis. *Arthritis Rheum* 1990;33:1108-13.
82. von Pirquet C, Schick B. Serum sickness. Baltimore: Williams & Wilkins, 1951.
83. Bielory L, Yancey KB, Young NS, Frank MM, Lawley TJ. Cutaneous manifestations of serum sickness in patients receiving antithymocyte globulin. *J Am Acad Dermatol* 1985;13:411-7.
84. Warnington RJ, Martens CJ, Rubin M, Rutherford WJ, Aoki FY. Immunologic studies in subjects with a serum sickness-like illness after immunization with human diploid cell rabies vaccine. *J Allergy Clin Immunol* 1987;79:605-10.
85. Wintroub BU, Siem R. Cutaneous drug reactions: pathogenesis and clinical classification. *J Am Acad Dermatol* 1985;13:167-79.
86. Dubost JJ, Souteyrand P, Sauvezie B. Drug-induced vasculitides. *Baillieres Clin Rheumatol* 1991;5:119-38.
87. Brasile L, Kremer JM, Clarke JL, Cerilli J. Identification of an autoantibody to vascular endothelial cell-specific antigens in patients with systemic vasculitis. *Am J Med* 1989;87:74-80.
88. Falk RJ, Jennette JC. Anti-neutrophil cytoplasmic autoantibodies with specificity for myeloperoxidase in patients with systemic vasculitis and idiopathic necrotizing and crescentic glomerulonephritis. *N Engl J Med* 1988;318:1651-7.
89. Ekenstam EAF, Callen JP. Cutaneous leukocytoclastic vasculitis: clinical and laboratory features of 82 patients seen in private practice. *Arch Dermatol* 1984;120:484-9.
90. Sanchez NP, Van Hale HM, Su WP. Clinical and histopathologic spectrum of necrotizing vasculitis: report of findings in 101 cases. *Arch Dermatol* 1985;121:220-4.
91. Van Hale HM, Gibson LE, Schroeter AL. Henoch-Schönlein vasculitis: direct immunofluorescence study of uninvolved skin. *J Am Acad Dermatol* 1986;15:665-70.
92. Hoffman GS, Kerr GS, Leavitt RY, et al. Wegener granulomatosis: an analysis of 158 patients. *Ann Intern Med* 1992;116:488-98.
93. D'Crux D, Hughes G. Systemic vasculitis: new tests, new treatments. *BMJ* 1992;304:269-70.
94. Werner MC, Romaldini JH, Bromberg N, Werner RS, Farah CS. Adverse effects related to thionamide drugs and their dose regimen. *Am J Med Sci* 1989;297:216-9.
95. Carrasco MD, Riera C, Clotet B, Grifol M, Foz M. Cutaneous vasculitis associated with propylthiouracil therapy. *Arch Intern Med* 1987;147:1677.
96. Horton RC, Sheppard MC, Emery P. Propylthiouracil-induced systemic lupus erythematosus. *Lancet* 1989;2:568.
97. Dolman KM, Gans RO, Vervaat TJ, et al. Vasculitis and antineutrophil cytoplasmic autoantibodies associated with propylthiouracil therapy. *Lancet* 1993;342:651-2.
98. Dwyer JM, Kenicer K, Thompson BT, et al. Vasculitis and retinoids. *Lancet* 1989;2:494-6.
99. Hummer D, Cohen JD, Majadla R, Dux S. Hypersensitivity vasculitis due to ofloxacin. *BMJ* 1989;299:303.
100. Taylor RJ. Hypersensitivity vasculitis occurring in a patient receiving immunotherapy. *J Allergy Clin Immunol* 1991;87:889-90.
101. Heckbert SR, Stryker WS, Coltin K, Manson JE, Platt R. Serum sickness in children after antibiotic exposure: estimates of occurrence and morbidity in a health maintenance organization population. *Am J Epidemiol* 1990;132:336-42.
102. Platt R, Dreis MW, Kennedy DL, Kuritsky JN. Serum sickness-like reactions to amoxicillin, cefaclor, cephalixin, and trimethoprim-sulfamethoxazole. *J Infect Dis* 1988;158:474-7.
103. Yen MC, Piszczek JE, Mintzer DL. Serum sickness-like syndrome associated with propranolol therapy. *Postgrad Med* 1983;74:291-4.
104. Puyana J, Urena V, Quirce S, Fernandez-Rivas M, Cuevas M, Fraj J. Serum sickness-like syndrome associated with minocycline therapy. *Allergy* 1990;45:313-5.
105. Noel J, Rosenbaum LH, Gangadharan V, Stewart J, Galens G. Serum sickness-like illness and leukocytoclastic vasculitis following intracoronary arterial streptokinase. *Am Heart J* 1987;113:395-7.
106. Bauer KA. Coumarin-induced skin necrosis. *Arch Dermatol* 1993;129:766-8.
107. Comp PC. Coumarin-induced skin necrosis: incidence, mechanisms, management and avoidance. *Drug Safety* 1993;8:128-35.
108. Teepe RG, Broekmans AW, Vermeer BJ, Nienhuis AM, Loeliger EA. Recurrent coumarin-induced skin necrosis in a patient with an acquired functional protein C deficiency. *Arch Dermatol* 1986;122:1408-12.
109. Vigano D'Angelo S, Comp PC, Esmon CT, D'Angelo A. Relationship between protein C antigen and anticoagulant activity during oral anticoagulation and in selected disease states. *J Clin Invest* 1986;77:416-25.
110. Schramm W, Spannagl M, Bauer KA, et al. Treatment of coumarin-induced skin necrosis with a monoclonal antibody purified protein C concentrate. *Arch Dermatol* 1993;129:753-6.
111. Miletich J, Sherman L, Broze G Jr. Absence of thrombosis in subjects with heterozygous protein C deficiency. *N Engl J Med* 1987;317:991-6.
112. Grimaudo V, Guessaz F, Hauert J, Sarraj A, Kruthof EK, Bachmann F. Necrosis of skin induced by coumarin in a patient deficient in protein S. *BMJ* 1989;298:233-4.
113. MacLean JA, Moscicki R, Bloch KJ. Adverse reactions to heparin. *Ann Allergy* 1990;65:254-9.
114. Tuneu A, Moreno A, de Moragas JM. Cutaneous reactions secondary to heparin injections. *J Am Acad Dermatol* 1985;12:1072-7.
115. Kelly RA, Gelfand JA, Pincus SH. Cutaneous necrosis caused by systemically administered heparin. *JAMA* 1981;246:1582-3.
116. Kelton JG, Sheridan D, Santos A, et al. Heparin-induced thrombocytopenia: laboratory studies. *Blood* 1988;72:925-30.
117. Buchner BS, Lichtenstein LM. Anaphylaxis. *N Engl J Med* 1991;324:1785-90.

131. Horan RF, Schneider LC, Sheffer AL. Allergic skin disorders and mastocytosis. *JAMA* 1992;268:2858-68.

132. International Rheumatic Fever Study Group. Allergic reactions to long-term benzathine penicillin prophylaxis for rheumatic fever. *Lancet* 1991; 337:1308-10.

133. Megerian CA, Arnold JE, Berger M. Angioedema: 5 years' experience, with a review of the disorder's presentation and treatment. *Laryngoscope* 1992;102:256-60.

134. Hedner T, Samuelsson O, Lunde H, Lindholm L, Andren L, Wiholm BE. Angio-oedema in relation to treatment with angiotensin converting enzyme inhibitors. *BMJ* 1992;304:941-6.

135. Thompson T, Frable MA. Drug-induced, life-threatening angioedema revisited. *Laryngoscope* 1993;103:10-2.

136. Bielory L, Lee SS, Holland CL, Jaker M. Long-acting ACE inhibitor-induced angioedema. *Allergy Proc* 1992;13:85-7.

137. Slater EE, Merrill DD, Guess HA, et al. Clinical profile of angioedema associated with angiotensin converting-enzyme inhibition. *JAMA* 1988; 260:967-70.

138. Anderson MW, deShazo RD. Studies of the mechanism of angiotensin-converting enzyme (ACE) inhibitor-associated angioedema: the effect of an ACE inhibitor on cutaneous responses to bradykinin, codeine, and histamine. *J Allergy Clin Immunol* 1990;85:856-8.

139. Verresen L, Waer M, Vanrenterghem Y, Michielsen P. Angiotensin-converting-enzyme inhibitors and anaphylactoid reactions to high-flux membrane dialysis. *Lancet* 1990;336:1360-2.

140. Parnes EL, Shapiro WB. Anaphylactoid reactions in hemodialysis patients treated with the AN69 dialyzer. *Kidney Int* 1991;40:1148-52.

141. Brunet P, Jaber K, Berland Y, Baz M. Anaphylactoid reactions during hemodialysis and hemofiltration: role of associating AN69 membrane and angiotensin I-converting enzyme inhibitors. *Am J Kidney Dis* 1992;19: 444-7.

142. Kessler DA. Introducing MEDWatch: a new approach to reporting medication and device adverse effects and product problems. *JAMA* 1993; 269:2765-8.

143. Moore N, Biour M, Paux G, et al. Adverse drug reaction monitoring: doing it the French way. *Lancet* 1985;2:1056-8.

Massachusetts Medical Society
 Registry on Continuing Medical Education

To obtain information on continuing medical education courses in the New England area, call between 9:00 a.m. and 12:00 noon, Monday through Friday, (617) 893-4610 or in Massachusetts 1-800-322-2303, ext. 1342.

des. Bail
 aut
 h sye
 di
 ulitis and
 gl J Med
 s: clinical
 h Derma-
 spectrum
 Dermatol
 vasculitis:
 Dermatol
 atosis: an
 nts. BMJ
 Adverse
 Med Sci
 asculitis
 7:1677.
 -systemic
 utrophil
 y. Lan-
 etinoids.
 litis due
 ving im-
 sickness
 orbidity
 of 1990
 ke r
 ielt
 associ-
 Fraj J.
 Aller-
 Serum
 racoro-
 93:129:
 s, man-
 er EA.
 quired
 onship
 l anti-
 7:416-
 marin-
 con-
 s with
 inn F
 in S
 Ann
 try to
 stem-
 tope-
 324